

Use of paclitaxel-coated balloon to treat in-stent restenosis in femoropopliteal segments

O uso do balão com paclitaxel no tratamento da reestenose intra-stent no segmento fêmoro-poplíteo

Julio Cesar Peclat de Oliveira¹, Ana Paula Rolim Maia Peclat¹, Fernando Tebet Ramos Barreto¹, João Marcos Fonseca¹, Diogo Di Batista de Abreu e Souza¹, Stenio Karlos Alvim Fiorelli¹, Rossano Kepler Alvim Fiorelli², Marcos Arêas Marques³

Abstract

Background: In-stent restenosis due to myointimal hyperplasia after angioplasty is common and limits long-term patency. Treatments using balloons coated with antiproliferative drugs may offer an alternative option for this pathology.

Objectives: To demonstrate the efficacy and complications (death, major amputations, etc.) of drug-coated balloons for treatment of in-stent restenosis in femoropopliteal segments. **Methods:** This was a retrospective cohort study of 32 consecutive patients treated between 2012 and 2016 who underwent treatment to correct in-stent restenosis in the femoropopliteal segment using paclitaxel-coated balloons. The success rate was measured in terms of technical success and restenosis of less than 50% on Doppler ultrasonography at 30, 90, and 180 days after the procedure.

Results: Four patients (12.5%) exhibited restenosis greater than 50%, one (3.1%) after 90 days and three (9.4%) after 180 days, equating to a success rate of 87.5% of procedures, and by 180 days all patients experienced improvement or cessation of the signs and/or symptoms they had presented prior to the procedure. There were no deaths and complications occurred in just 2 cases in the immediate postoperative period. **Conclusions:** Short-term results are promising, with reductions in the magnitude of restenosis and a low rate of complications. Further studies are needed that can demonstrate the long-term effects and the economic impacts in comparison to other procedures.

Keywords: peripheral artery disease; balloon angioplasty; vascular graft restenosis.

Resumo

Contexto: A reestenose intra-stent por hiperplasia miointimal pós-angioplastia é uma intercorrência frequente e que limita a perviabilidade do procedimento a longo prazo. A terapia com balões revestidos de droga com ação antiproliferativa pode ser uma alternativa no tratamento dessa complicação. **Objetivos:** Demonstrar eficácia e as complicações (óbito, grandes amputações, etc.) do balão farmacológico no tratamento da reestenose intra-stent de segmento femoropoplíteo. **Métodos:** Estudo de coorte retrospectivo de 32 pacientes consecutivos tratados entre os anos de 2012 e 2016, submetidos a terapia de reestenose intra-stent de segmento femoropoplíteo com angioplastia com balão farmacológico revestido com paclitaxel. A taxa de sucesso foi mensurada pela ocorrência de sucesso do procedimento e reestenose inferior a 50% em avaliação por eco-Doppler colorido 30, 90 e 180 dias após o procedimento.

Resultados: Quatro pacientes (12,5%) apresentaram reestenose superior a 50%, sendo um (3,1%) após 90 dias e três (9,4%) após 180 dias, conferindo uma taxa de sucesso de 87,5% ao procedimento. Após 180 dias, todos os pacientes referiam melhora ou cessação dos sinais e/ou sintomas apresentados antes do procedimento. Não houve óbitos, e complicações ocorreram apenas em dois casos, no pós-operatório imediato. **Conclusões:** Os resultados a curto prazo da terapia com balão farmacológico são promissores, com redução na taxa de reestenose e baixo índice de complicações. Ainda precisam ser apresentados estudos demonstrando os efeitos a longo prazo dessa terapia, assim como seu impacto econômico quando comparada a outros procedimentos.

Palavras-chave: doença arterial periférica; angioplastia; reestenose de enxerto vascular.

¹Clínica Julio Peclat, Departamento de Cirurgia Vascular, Rio de Janeiro, RJ, Brazil.

²Universidade Federal do Estado do Rio de Janeiro – UNIRIO, Hospital Universitário Gaffrée e Guinle, Rio de Janeiro, RJ, Brazil.

³Universidade do Estado do Rio de Janeiro – UERJ, Hospital Universitário Pedro Ernesto – HUPE, Rio de Janeiro, RJ, Brazil.

Financial support: None.

Conflicts of interest: No conflicts of interest declared concerning the publication of this article.

Submitted: December 22, 2016. Accepted: February 23, 2017.

The study was carried out at Clínica Julio Peclat, Rio de Janeiro, RJ, Brazil.

■ INTRODUCTION

Compromise to blood perfusion of the lower limbs in peripheral arterial disease (PAD) is an event of elevated potential morbidity. Although initial success rates after percutaneous transluminal balloon angioplasty (PTBA), restenosis rates can be as high as 60% within 1 year.¹ Conventional stents (CS) have been used to attempt to reduce rates of this complication, with a certain degree of success. However, rates of in-stent restenosis (ISR) are still relatively high, at 18 to 37% at 1 year after treatment with CS in femoropopliteal segments (Figure 1).²

Treatment options for ISR include PTBA and placement of a new CS, with fairly unsatisfactory results, and newly developed technologies, such as drug-coated balloons (DCBs), of which the most well-known is coated with paclitaxel, which has antiproliferative effects on the artery wall.

The objectives of this study are to investigate the efficacy of using DCBs as a treatment option for ISR, and to analyze the occurrence of complications related to their use.

■ METHODS

A retrospective analysis was conducted of the medical records of a cohort of patients who had been treated with percutaneous transluminal angioplasty of femoropopliteal segments between 2012 and

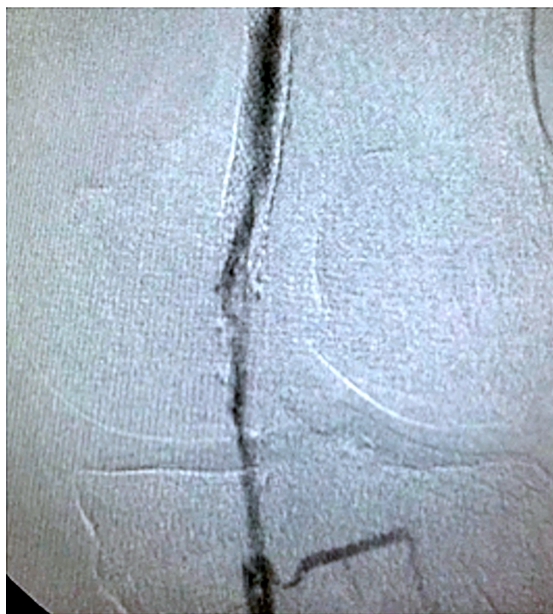

Figure 1. Pretreatment arteriography showing in-stent restenosis of approximately 85% at the most critical point, at the femoropopliteal transition.

2016. The cohort comprised 32 patients (19 males and 13 females) aged from 56 to 77 years (mean: 66.5 years) who met the inclusion criteria proposed for the study: ISR greater than 50% (peak systolic velocity > 180 cm/s) for more than 3 months, mild claudication, and minor tissue damage (Rutherford 2-5), at least one artery draining as far as the foot, and lesion length of less than 27 cm. The exclusion criteria (all of those used for the COPA CABANA Trial³) were as follows: more than two simultaneous lesions, stent fracture, failure to recanalize the lesion, acute thrombosis, and proximal lesion with no prior treatment, in addition to participation of patient in other similar studies.

Intervals between the primary procedure and diagnosis and treatment of ISR ranged from 6 months to 5 years. Twenty-four patients (75%) were treated with an IN.PACT™ Admiral® DCB (Medtronic®) and eight (25%), with a Lutonix® DCB (Bard®).

Technical success was defined as residual stenosis of the target lesion of less than 30%, based on comparison of pre-angioplasty and post-angioplasty intraoperative arteriographies. Greater than 30% stenosis, acute thrombosis, distal embolism, and dissection were all defined as technical failure.

The procedure was considered satisfactory when technical success was achieved and observed restenosis was less than 50%, based on comparison of preoperative color Doppler ultrasonography findings of examinations conducted with the same technique at 30, 90, and 180 days by the same professional who had conducted the examination in which ISR was detected, in accordance with routine procedure at the service. Patients' signs and symptoms (presence and intensity of claudication and of pain at rest, presence or absence of trophic ulcers with ischemic characteristics on the lower limbs) and any complications suffered were also analyzed.

None of the study participants were excluded because of loss to follow-up or because any of the information needed for the study was missing.

This study was granted Research Ethics Committee approval.

■ RESULTS

The mortality rate of this procedure was zero. The length of postoperative hospital stay varied from 1 to 4 days and there were complications during the immediate postoperative period in two patients (non-surgical hematoma at the puncture site and elevated nitrogen retention).

At 6-month follow-up, all 32 patients reported that the symptoms that they had experienced before intervention with the DCB had either improved or disappeared and also reported increases in the distances they were able to walk without claudication, healing of trophic ulcers, and absence of lower limb pain at rest (Table 1). No major amputations (above the ankle) were necessary.

By the final follow-up appointment, four patients (12.5%) exhibited restenosis greater than 50%, one (3.1%) at 90 days and three (9.4%) at 180 days after the arterial color Doppler ultrasonography, equating to a success rate of 87.5% of procedures (Table 2 and Figure 2).

DISCUSSION

The superiority of DCBs in comparison to CS has already been shown in several studies investigating angioplasty of the superficial femoral artery, revealing better primary patency and reductions in rates of interventions because of complications.⁴⁻⁶ In addition to improved efficacy in terms of improvement of symptoms, time free from reintervention, and reductions in amputation rates, studies have also shown that the procedures have similar levels of safety, which is understandable considering the similar techniques employed.

The results achieved in our sample of patients are compatible with those reported in published studies

Table 1. Changes to symptoms during follow-up, graded according to the Rutherford criteria (0 = preoperative condition).

Rutherford	Time (days)			
	0	30	90	180
0	- (0%)	8 (25%)	11 (34.4%)	16 (50%)
1	- (0%)	11 (34.4%)	15 (46.9%)	13 (40.6%)
2	7 (21.8%)	10 (31.2%)	4 (12.5%)	3 (9.4%)
3	12 (37.5%)	- (0%)	- (0%)	- (0%)
4	8 (25%)	- (0%)	- (0%)	- (0%)
5	5 (15.7%)	3 (9.4%)	2 (6.2%)	- (0%)
6	- (0%)	- (0%)	- (0%)	- (0%)
Total	32 (110%)	32 (110%)	32 (110%)	32 (110%)

Table 2. Results at 30, 90, and 180 days follow-up after in treatment of in-stent restenosis, assessed with color Doppler ultrasound.

	RESULTS		
	30 days	90 days	180 days
Success	32 (100%)	31 (96.9%)	28 (87.5%)
Failure	0 (0%)	1 (3.1%)	4 (12.5%)

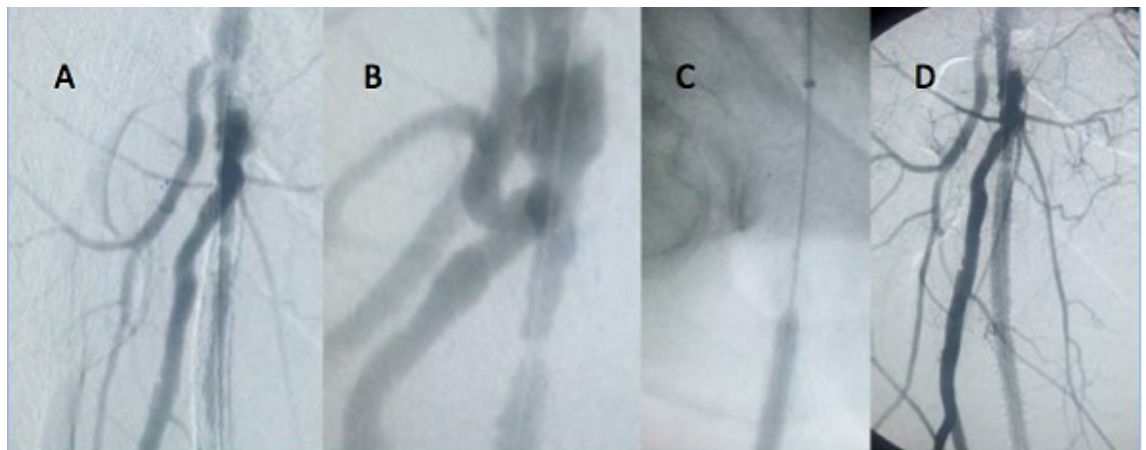


Figure 2. Angioplasty for in-stent stenosis in one of the cases in the study sample. (A) extensive in-stent stenosis; (B) zoomed image of the area of occlusion in the proximal portion of the stent; (C) pharmacological balloon angioplasty; (D) final control image, with improvement to earlier lesions.

of ISR treatment using DCBs.^{3,7} However, so far there have been few studies investigating this subject and those that exist do not report long-term results.

There are currently a number of ongoing studies investigating the efficacy of DCBs for ISR in the superficial femoral artery, among which the PLAISIR Study, the ISAR-PEBIS RCT, and the PACUBA I RCT are of note.³

Another point of interest is the cost-benefit relationship offered by DCBs in comparison to PTBA and CS. There are studies that suggest that DCBs are better in this respect.⁸

This was a short-term retrospective study of a limited number of patients, in which some possible sources of bias, such as follow-up with more than one sonographer, varied types of stents, were not assessed blind, insufficient evaluation of quality of life, costs, and economic impact. Therefore, we are aware that prospective studies are needed to enable assessment of whether the superior short-term results can be reproduced over the medium and long term, and also to compare the cost-benefit profile of DCBs to those of other types of intervention.

CONCLUSIONS

Treatment of ISR with paclitaxel-coated balloons is feasible, it can be performed safely (the incidence of complications related to the method was low and mortality was zero), and it demonstrates excellent short-term results.

REFERENCES

1. Reekers JA, Vries CJM. A decade of drug-eluting technology in peripheral arterial disease: blurred by dissembling evidence. *Cardiovasc and Intv Radiol*. 2016;39(12):1678-80. PMID:27671154. <http://dx.doi.org/10.1007/s00270-016-1476-1>.
2. Sobieszcyk P. In-stent restenosis after femoropopliteal interventions with drug-eluting stents. *J Am Coll Cardiol Intv*. 2016;9(8):835-7. PMID:27101909. <http://dx.doi.org/10.1016/j.jcin.2016.02.015>.
3. Tepe G. The Copacabana study: DEB vs. POBA in in-stent restenosis. Leipzig: LINC; 2015 [citado 2016 dez 22]. http://linc2015.cloudcontrolled.com/media/15t_1_1620_Tepe.pdf.
4. Rosenfield K, Jaff MR, White CJ, et al. Trial of a paclitaxel-coated balloon for femoropopliteal artery disease. *N Engl J Med*. 2015;373(2):145-53. PMID:26106946. <http://dx.doi.org/10.1056/NEJMoa1406235>.
5. Schmidt A, Piorkowski M, Görner H, et al. Drug-coated balloons for complex femoropopliteal lesions: 2-year results of a real-world registry. *J Am Coll Cardiol Intv*. 2016;9(7):715-24. PMID:27056311. <http://dx.doi.org/10.1016/j.jcin.2015.12.267>.
6. Laird JR, Schneider PA, Tepe G, et al. Durability of treatment effect using a drug-coated balloon for femoropopliteal lesions: 24-month results of IN.PACT SFA. *J Am Coll Cardiol*. 2015;66(21):2329-38. PMID:26476467. <http://dx.doi.org/10.1016/j.jacc.2015.09.063>.
7. Herten M, Torsello GB, Schönefeld E, Stahlhoff S. Critical appraisal of paclitaxel balloon angioplasty for femoral-popliteal arterial disease. *Vasc Health Risk Manag*. 2016;12:341-56. PMID:27621646. <http://dx.doi.org/10.2147/VHRM.S81122>.
8. Pietzsch JB, Geisler BP, Zeller T. Endovascular interventions for treatment of femoropopliteal peripheral artery disease: updated budget impact analysis for Germany based on latest clinical evidence. *Value Health*. 2015;18(7):A349. PMID:26531975. <http://dx.doi.org/10.1016/j.jval.2015.09.632>.

Correspondence

Julio Cesar Peclat de Oliveira
Avenida Ayrton Senna, 3000, bloco 1, salas 117-120 - Via Parque
Offices
CEP 22775-001 - Rio de Janeiro (RJ), Brazil
Tel.: +55 (21) 2421-9017
E-mail: julioceclat@yahoo.com.br

Author information

JCPO, FTRB, JMF, DBAS and SKAF - Vascular surgeons, Clínica Julio Peclat.
APRMP - Clinical physician, Clínica Julio Peclat.
RKAF - Professor, Universidade Federal do Estado do Rio de Janeiro (UNIRIO).
MAM - Angiologist, Hospital Universitário Pedro Ernesto (HUPE), Universidade do Estado do Rio de Janeiro (UERJ).

Author contributions

Conception and design: JCPO, APRMP, RKAF
Analysis and interpretation: JCPO, APRMP, RKAF
Data collection: JCPO, APRMP, RKAF, FTRB, JMF, DBAS, SKAF
Writing the article: JCPO, RKAF, MAM
Critical revision of the article: JCPO, RKAF, MAM
Final approval of the article*: JCPO, APRMP, RKAF, FTRB, JMF, DBAS, SKAF, MAM
Statistical analysis: JCPO, RKAF, MAM
Overall responsibility: JCPO, APRMP, RKAF

*All authors have read and approved of the final version of the article submitted to *J Vasc Bras*.